

DORSAL PLUS VENTRAL ORAL MUCOSAL GRAFT BULBAR URETHROPLASTY

Enzo Palminteri and Elisa Berdondini.

Center for Urethral and Genitalia Reconstructive Surgery. Arezzo. Italy.

Summary.- Traditionally, anastomotic procedures with transection and urethral excision are suggested for short bulbar strictures, while longer strictures are treated by patch graft urethroplasty preferably using the buccal mucosa as gold-standard material due to its histological characteristics.

However, anastomotic urethroplasties may cause sexual complications related to vascular damage of the spongiosum following the urethral section or to excessive urethral shortening.

On the other hand, one-sided graft procedures, using either dorsal or ventral graft location, could be insufficient

in providing a lumen of adequate width in strictures with a particularly narrow area.

The double buccal graft urethroplasty is a new technique that aims to obtain a sufficient "two-sided" augmentation of the urethra avoiding its transection and preserving the urethral plate.

In this chapter we discuss the rationale for utilizing our procedure. In addition, the surgical technique is described in detail.

Keywords: Urethra. Urethral stricture. Urethroplasty. Graft. Oral Mucosa.

Resumen.- OBJETIVO:



CORRESPONDENCE

Enzo Palminteri
Center for Urethral Surgery, Arezzo
Piazza Monaco 10
52100 Arezzo (Italy)

enzo.palminteri@inwind.it

Palabras clave: G

INTRODUCCIÓN

Oral mucosa (OM) is considered the gold standard urethral substitute in graft bulbar urethroplasties and its dorsal or ventral placement using dorsal or ventral urethrotomy approaches has become a contentious issue without winners (1, 2). In 1996, Morey and McAninch described the ventral grafting by a ventral urethrotomy which provides an easy access to the urethra and a good visualisation of the stricture (3). In the same year, Barbagli introduced the novelty of the dorsal grafting by the dorsal urethrotomy (4). Nevertheless, in time, the same Author recognised that dorsal approach is simpler in the distal bulbar urethra, whereas ventral approach with ventral grafting is more efficacious in the proximal bulbar urethra, where the spongiosum tissue is thick. Also he warned that the dorsal access might damage the erectile function and the bulbar arteries when the dissection from the corpora needs to be very proximal. Moreover, the dorsal urethral mobilisation turned out to be difficult in scarred urethras with marked periurethral fibrosis following prior treatments and an extensive dorsal approach could cause urethral ischemia. Therefore, in 2001, Asopa described a different dorsal grafting by a ventral urethrotomy approach stating that the procedure is easier because the urethra is not mobilized (5). Recently, Kulkarni and Barbagli elaborated a modified dorso-lateral approach which preserves one lateral vascular supply to the urethra reducing the urethral mobilization (6).

In 2008, we described for the first time, the combined dorsal plus ventral graft (DVG) for the repair of very tight bulbar strictures (7) in which one-side graft urethroplasties may not be sufficient to provide a lumen of adequate width and anastomotic techniques may cause sexual complications due to the transecting and shortening of the urethra. In these strictures, the two-sided grafting by means of the simpler ventral approach has showed to provide an adequate urethral augmentation, preserving the narrow urethral plate (8) avoiding postoperative sexual complications. We present herein, step by step, this surgical technique.

SURGICAL TECHNIQUE

Patient selection

The dorsal plus ventral oral mucosal graft urethroplasty is suggested for the repair of tight bulbar strictures characterized by a narrow residual urethral plate, scarred and compromised by stenotic rings, in which a single patch appears inadequate to obtain a sufficiently wide lumen. Preoperative retrograde-voi-

ding urethrography and urethroscopy give information regarding the site, length and degree of urethral narrowing; however the choice of the optimal surgical technique will be determined by the intraoperative urethral conditions.

Patient preparation

A double-team approach is used, with one team exposing the stricture, while the other harvests the OM.

The Kilner-Doughty retractor provides an excellent oral exposure, making it easy to work either with orotracheal or nasotracheal intubation. One assistant is sufficient for the harvesting. Two OM grafts are harvested from both cheeks, or a wide single graft is harvested from one cheek and subsequently tailored into two smaller grafts according to the length of the dorsal and ventral urethral openings. The oral donor site is closed with 4-zero polyglactin interrupted stitches or running suture.

The patient's lower extremities are carefully placed in Allen stirrups and the patient is placed in the lithotomy position. Proper positioning ensures that there is no pressure on any part of the calf muscles and no inward boot rotation, so as to avoid perineal nerve injury. The skin of the suprapubic region, scrotum and perineum is shaved and this region is prepared and draped appropriately.

Preoperatively, urethroscopy is performed and a Sensor 3 F guidewire is inserted through the urethra into the bladder. Methylene blue is injected into the urethra. The distal site of the stricture is identified by inserting a 18 F plastic Nelaton catheter with a round tip. Incision is made. Once it is outlined, an Y-inverted perineal incision is made.

Dorsal plus Ventral Graft Bulbar repair

The bulbocavernous muscles are gently divided in the mid-line (Figure 1). The bulbar urethra is ventrally exposed. Using a ventral-sagittal urethrotomy (Figure 2) the strictured urethra is opened with the aid of the guide wire and the methylene blue previously injected to define the narrow lumen: this step avoids losing the lumen and does not damage the urethral plate during the urethral opening. The urethra is left open for 1 cm both proximally and distally in the healthy urethra.

Dorsal Graft: the exposed dorsal urethra is incised in the mid-line down to the tunica (Figure 3); the margins of the incised dorsal urethra are dissected from the tunica albuginea without lifting the two

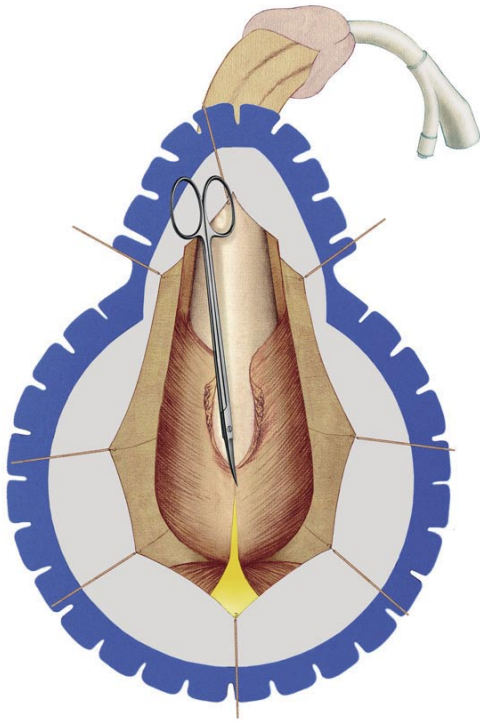


Figure 1. The bulbocavernosus muscles are gently divided in the mid-line, leaving the lateral margins of the muscle intact. The bulbar urethra is ventrally exposed.

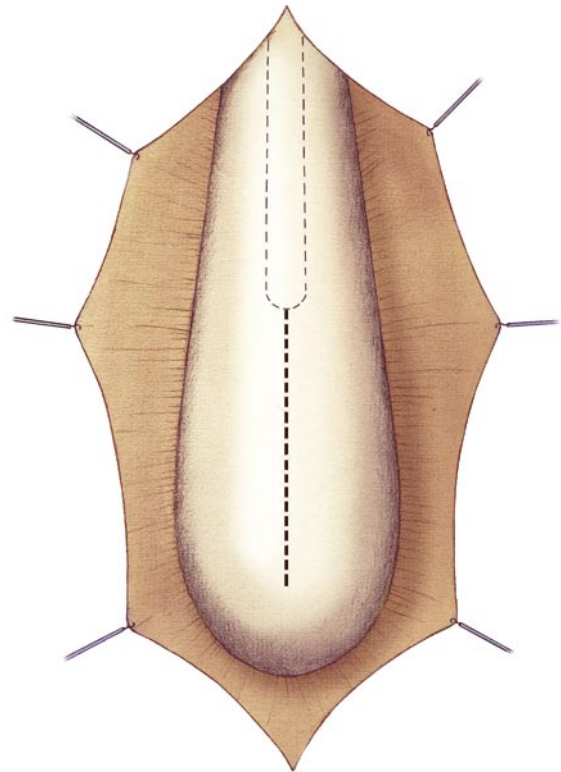


Figure 2. Using a ventral-sagittal urethrotomy the strictured urethra is opened.

halves of the bisected urethra: an elliptical raw area is created (Figure 4) where the first graft is placed, quilted to the corpora cavernosa and sutured to the urethral margins (Figure 5).

Ventral Graft: following dorsal augmentation, the urethra is also graft-enlarged ventrally. The second graft is sutured laterally to the left mucosal margin of the urethral plate with a running suture 6-zero (Figure 6). The catheter is inserted; the graft is rotated and sutured laterally to the right mucosal margin (Figure 7).

An inverted ventral graft quilting is made with few stitches fixing the spongiosum to the graft (Figure 8). Finally the adventitia of the spongiosum is closed over the graft with 4-zero running suture (Figure 9).

Post-operative care

An ice bag is applied on the cheek to avoid pain and haematoma. A clear liquid diet and ice-cream are initially given, and subsequently the patient can pass to a soft and regular diet.

The patient ambulates on the second postoperative day and is discharged from the hospital 3

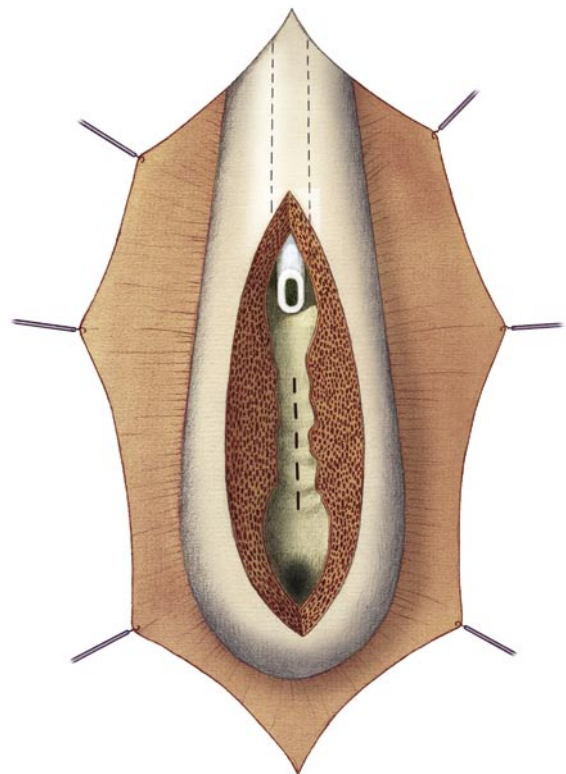


Figure 3. The exposed dorsal urethra is incised in the mid-line down to the tunica.

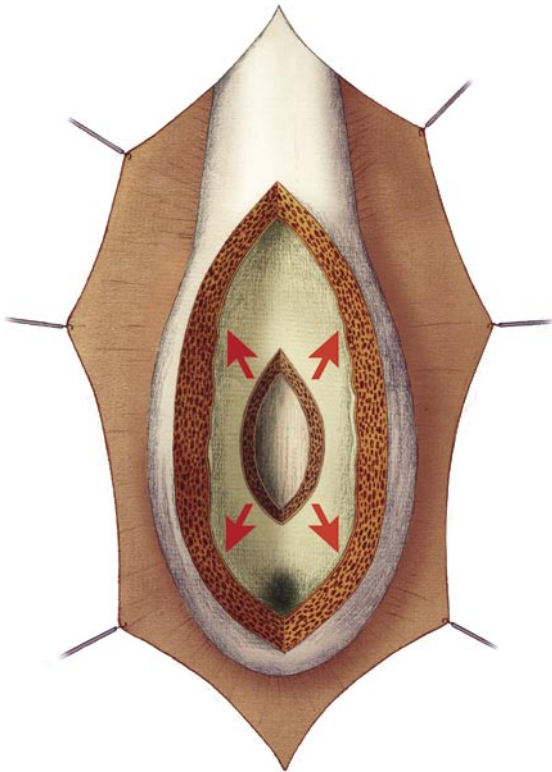


Figure 4. The margins of the incised dorsal urethra are dissected from the tunica albuginea without lifting the two halves of the bisected urethra: an elliptical raw area is created.

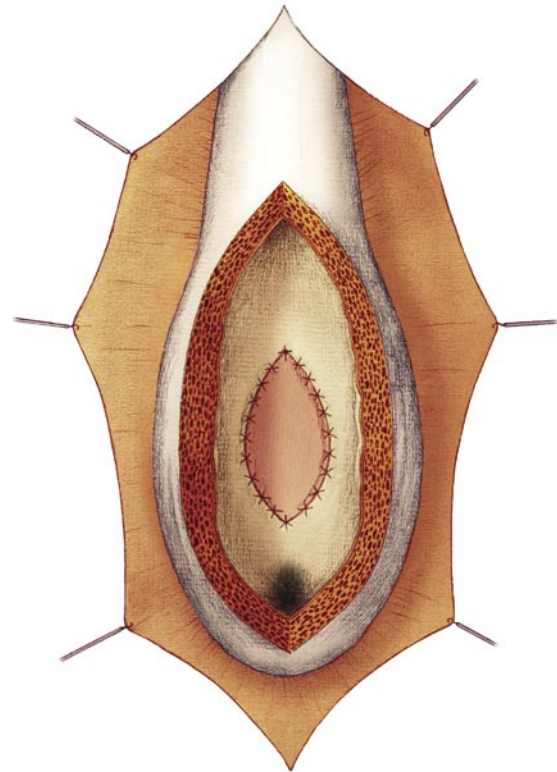


Figure 5. The first graft (Dorsal Graft) is placed in the elliptical raw area, quilted to the corpora cavernosa and sutured to the urethral margins.

days after surgery. All patients are prescribed post-operative broad-spectrum antibiotics and afterwards continue with oral antibiotics until the catheter is removed. Voiding cysto-urethrography is performed upon catheter removal, 3 weeks after surgery.

DISCUSSION

Easiness and Versatility of the Ventral Urethrotomy Approach

Traditionally, the ventral urethrotomy has been considered an easy access to the urethral lumen which gives a good visualisation of the strictured tract (3, 9). As there is no mobilization-rotation of the urethra, it is very safe and simple to perform, particularly for reconstructive urologists in training, with little experience.

The urethral plate (size, mucosal edges and urethral lumen) is better visualized, allowing a water-tight graft-urethra anastomosis.

Furthermore, the ventral opening, following the evaluation of the stricture and its length, may

allow either dorsal or ventral or dorsal-ventral graft augmentation and, if necessary, excision of the scarred urethra with conversion into an anastomotic procedure (10).

Double Graft versus Single Graft

Usually dorsal or ventral single graft urethroplasties are performed without resection of any diseased tissues, while the double dorsal-ventral graft enlargement allows the partial removal of the fibrotic tissues without jeopardizing the creation of a sufficiently wide lumen in very tight strictures and reducing the risk of stenotic rings at the distal or proximal graft anastomotic sites (11, 12). Furthermore, reducing the width of a hypothetical single ventral graft, the double grafting may decrease the chance of fistulas and diverticulum.

However, to date, recent overviews have showed that ventral or dorsal single grafting procedures have a similar success rate (13, 14), while there are no comparative studies that can demonstrate the advantages of the double graft versus single graft techniques.

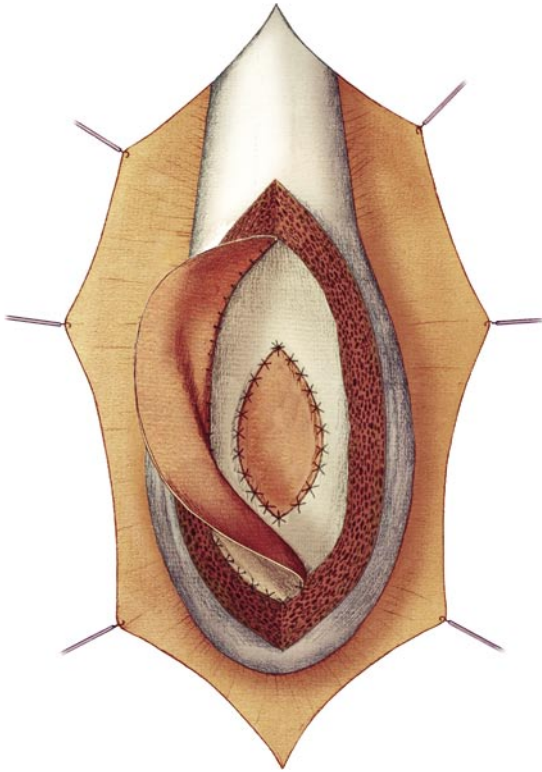


Figure 6. The second graft (Ventral Graft) is sutured laterally to the left mucosal margin of the urethral plate.

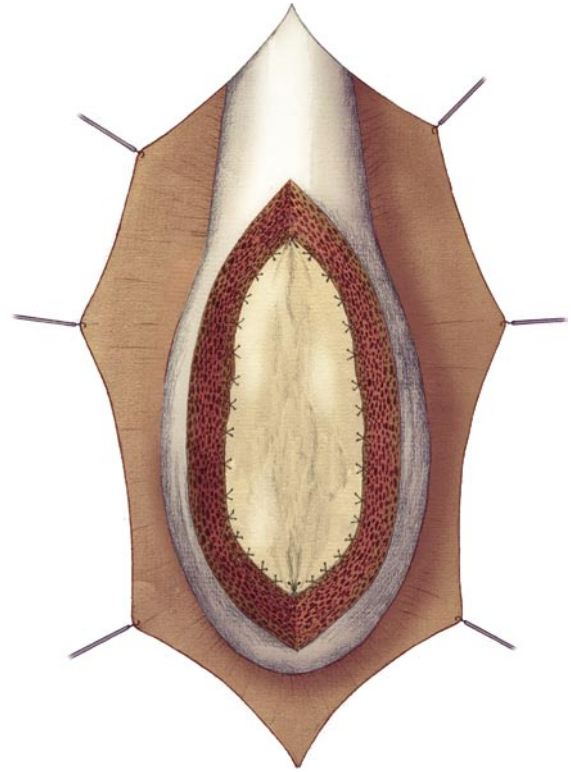


Figure 7. The catheter is inserted; the graft is rotated and sutured laterally to the right mucosal margin.

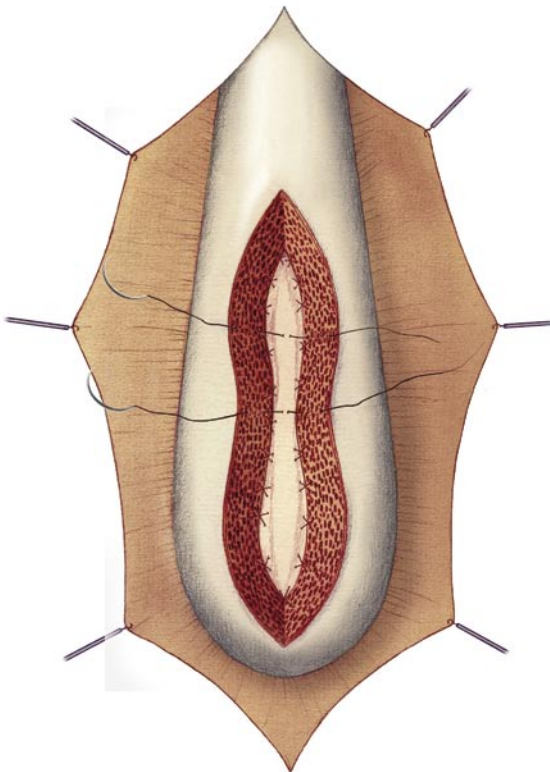


Figure 8. An inverted ventral graft quilting is made with few stitches fixing the spongiosum to the graft.

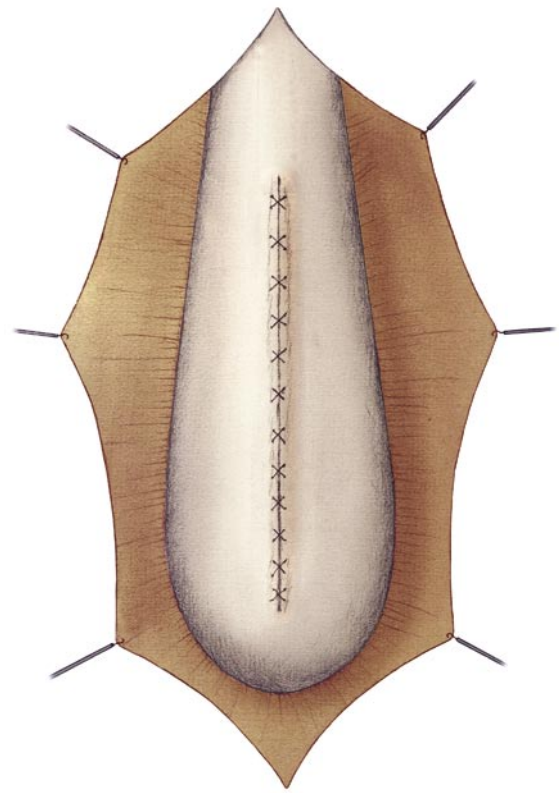



Figure 9. Finally the adventitia of the spongiosum is closed over the graft with 4-zero running suture.

Double Patch Graft versus Tube Graft

In the past, full circumferential urethral reconstruction using graft tubes has demonstrated a high rate of complications due to diverticulum, short stricture at the anastomotic sites or long stricture resulting from complete collapse of the entire tube (13). Differently, the double patch grafting with the support of the residual lateral strips of the urethral plate, allows a more stable and solid semi-circumferential reconstruction preserving the axial structure of the urethra and avoiding a circumferential graft-urethra anastomosis.


Double Graft versus Anastomotic procedures

In tight strictures the double graft allows avoiding the more aggressive anastomotic urethroplasties (AU) with urethral transection that may compromise the spongiosum vascularity. Avoiding the complete transversal section of the spongiosum, we stick to the important concept of preserving the urethral plate and urethral vascularity (10, 15). We also retained the original length of the urethral tube. Therefore our aim was to maintain the urethral axial integrity as much as possible and to reduce the sexual complications related to the anastomotic procedure, such as: penile curvature and shortening, decreased glans sensitivity, glans not full during erection, impaired erection, and so on. Some of these complications are related to the wide mobilization and shortening of the urethra. Others are perhaps related to vascular injury in the spongiosum distally to the urethral section. Overall, AUs showed a more significant impact on sexual life than that of graft techniques (16-23). 

However, in obliterative or traumatic strictures with hard scarring, the urethral plate may be ill-suited for enlargement, forcing its complete resection by an anastomotic procedure. Thereby, the choice of technique is always determined by the quality of the urethral plate.

Urinary and Sexual results of Dorsal plus Ventral double graft

Recently, we reviewed 73 patients who underwent dorsal-ventral BM graft urethroplasty for tight bulbar strictures between 2002 and 2010. The mean patient age was 39 yrs. Mean follow up was 48.9 months. Mean stricture length was 3.3 cm (range 1 to 10). Of these 73 cases, 64 (88%) were successful and 9 (12%) were failures with re-stricture. In 4 (5%) cases, the VCUG at catheter removal, showed a mild urethral leakage that resolved spontaneously with a prolonged catheterization.

The prevalence of postoperative sexual disorders was investigated using the validated questionnaire, previously adopted by Morey (18), and Coursey (22) in their series of urethroplasties. The questionnaire was administered one year after surgery to 49 sexually active patients. None of these men reported postoperative penile curvature or shortening, impaired erection, and dissatisfaction regarding erection or sexual activity compared to the pre-operative status. Moreover, erectile improvement was reported by 7 patients (14%), and all 49 (100%) patients reported overall satisfaction following urethroplasty. When compared to data reported by other authors using the same erectile function questionnaire following AUs, our data on DVGs showed better sexual results (16, 18). 

Sexual complications after AUs have an impact on the quality of life, which may be a more important issue than the risk of re-stricture. Therefore, successful outcomes in urethral repair should be assessed not only by objective voiding parameters but also by subjective parameters influencing patient satisfaction and the latter must be considered in the choice of surgical procedure. Larger series and adapted validated questionnaires reporting patient perception after urethroplasty will be necessary to establish whether dorsal-ventral double grafting techniques represent a valid alternative to either single grafting or traditional anastomotic techniques which are now supported by the current evidence as the method of choice.





CONCLUSIONS

The DVG technique is a safe, simple and reliable procedure which offers the possibility of performing a wide urethral enlargement in tight bulbar strictures by preserving at the same time the urethral plate and its length.

The use of appropriate surgical instruments and suture material are fundamental elements in avoiding post-operative complications and sequelae.

REFERENCES AND RECOMMENDED READINGS (*of special interest, **of outstanding interest)

1. Andrich DE, Mundy AR. What is the best technique for urethroplasty? *Eur Urol* 2008 54 (5): 1031-41.
2. Patterson JM, Chapple CR. Surgical techniques in substitution urethroplasty using buccal mucosa for the treatment of anterior urethral strictures. *Eur Urol* 2008 53 (6): 1162-71.

3. Morey AF, McAninch JW. When and how to use buccal mucosal grafts in adult bulbar urethroplasty. *Urology* 1996 48 (2): 194-8.
4. Barbagli G, Selli C, Tosto A, Palminteri E. Dorsal free graft urethroplasty. *J Urol* 1996; 155 (1): 123-6.
5. Asopa H, Garg M, Singhal GG, Singh L, Asopa J, Nischal A. Dorsal free graft urethroplasty for urethral stricture by ventral sagittal urethrotomy approach. *Urology* 2001 58 (5): 657-9.
6. Kulkarni S, Barbagli G, Sansalone S, Lazzeri M. One-sided anterior urethroplasty: a new dorsal onlay graft technique. *BJU Int* 2009 104 (8): 1150-55.
-  7. Palminteri E, Manzoni G, Berdondini E, et al. Combined dorsal plus ventral double buccal mucosa graft in bulbar urethral reconstruction. *Eur Urol* 2008 53 (1): 81-90.
-  8. Palminteri E, Berdondini E, Shokeir AA, Iannotta L, Gentile V, Sciarra A. Two-sided Bulbar Urethroplasty Using Dorsal Plus Ventral Oral Graft: Urinary and Sexual Outcomes of a New Technique. *J Urol* 2011 185 (5) :1766-71.
9. Wessels H, McAninch JW; Use of free grafts in urethral stricture reconstruction. *J Urol* 1996; 155: 1912-1915.
10. Abouassaly R and Angermeier KW; Augmented anastomotic urethroplasty. *J Urol*; 2007; 177: 2211-2215.
11. Barbagli G, Palminteri E, Guazzoni G, et al; Bulbar urethroplasty using buccal mucosa grafts placed on the ventral, dorsal or lateral surface of the urethra: are results affected by the surgical technique ? *J Urol* 2005; 174: 955-958.
12. Palminteri E, Berdondini E, Colombo F et al; Small intestinal submucosa (sis) graft urethroplasty: short-term results. *Eur Urol*; 2007; 51: 1695-1701.
13. Mangera A, Patterson MJ, Chapple CR; A systematic review of graft augmentation urethroplasty techniques for the treatment of anterior urethral strictures. *Eur Urol*; 2011; 59: 797-814.
14. Wang K, Miao X, Wang L, Li H; Dorsal versus ventral onlay urethroplasty for anterior urethral stricture: a meta-analysis. *Urol Int*; 2009; 83: 342-348.
15. Manzoni G, Bracka A, Palminteri E, et al; Hypospadias surgery: when, what and by whom ? *BJU Int.*; 2004; 94: 1188-1195.
-  16. Palminteri E, Berdondini E, Shokeir A, et al; Two-Sided Bulbar Urethroplasty Using Dorsal Plus Ventral Oral Graft: Urinary and Sexual Outcomes of a New Technique. *J Urol*; 2011; 185: 1766-1771. 
17. Guralnick ML, Webster GD; The augmented anastomotic urethroplasty: indications and outcome in 29 patients. *J Urol*; 2001; 165: 1496-1501.
18. Morey AF, Kizer WS; Proximal bulbar urethroplasty via extended anastomotic approach – what are the limits ? *J Urol*; 2006; 175: 2145-2149.
19. Barbagli G, De Angelis M, Romano G et al; Long-term followup of bulbar end-to end anastomosis: a retrospective analysis of 153 patients in a single center experience. *J Urol*; 2007; 178: 2470-2473.
20. Mundy AR; Results and complications of urethroplasty and its future. *Br J Urol*; 1993; 71: 322-325.
21. Al-Qudah HS and Santucci RA; Buccal mucosal onlay urethroplasty versus anastomotic urethroplasty (AU) for short urethral strictures: which is better? *J Urol*; suppl; 2006; 175: 103, abstract 313.
22. Coursey JW, Morey AF, McAninch JW et al; Erectile function after anterior urethroplasty. *J Urol*; 2001; 166: 2273-2276.
23. Kessler T, Fish M, Heitz M, et al; Patient satisfaction with the outcome of surgery for urethral strictures. *J Urol*; 2002; 167: 2507-2511.